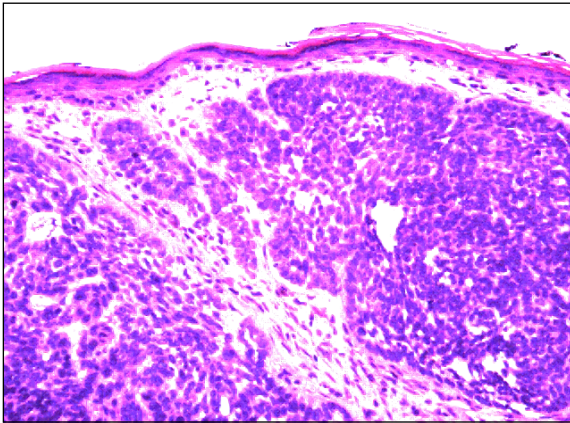
	5747 Hoover Blvd Tampa, Florida 33634		Patient Name SAMPLE, SAMPLE		Accession Number 1REL-04-04860	
	Phone: 813.884.2849 Fax: 813.890.0143		Sex F	Age (DOB) 82 (05/22/1922)	Account Number 1	Chart Number 42791
SAMPLE CLIENT 1234 Test Street Tampa, Florida 33333 813.123.4567			Requesting Physician SAMPLE PHYSICIAN, M.D.			Received 5/18/2004
			Referring Physician SAMPLE PHYSICIAN, M.D.			Reported 5/20/2004

Clinical Data

PIGMENTED LESIONS.

PATHOLOGY REPORT



SPECIMEN 01 SKIN, RIGHT ARM, SHAVE BIOPSY

MICROSCOPIC DESCRIPTION

Nests of atypical basaloid cell proliferation surrounded by a myxoid stroma are present. Peripheral palisading, individual cell necrosis and mitotic figures are present.

SPECIMEN 01, SKIN, RIGHT ARM, SHAVE BIOPSY:

DIAGNOSIS:

- Basal cell carcinoma.

GROSS DESCRIPTION: Received in formalin labeled with the patient's name and "right arm" is a piece of skin measuring 0.5 x 0.5 x 0.2 cm. The specimen is bisected and totally submitted in cassette 1A. mb/m

MICROSCOPIC DESCRIPTION: (Please see the microscopic description next to the picture.)

SPECIMEN 02, SKIN, LEFT UPPER ARM, PUNCH BIOPSY:

DIAGNOSIS:

- Dermatofibroma.

GROSS DESCRIPTION: Received in formalin labeled with the patient's name and "left upper arm" is a piece of skin measuring 0.6 X 0.5 X 0.4 cm. The specimen is bisected and totally submitted in cassette 2A. mb/m

MICROSCOPIC DESCRIPTION: Acanthosis with bridging rete ridges overlying a dermal lesion composed of spindled-shaped fibroblasts in a dense fibrous stroma.